

## Palm pollen as Growth and Metabolic Enhancer During the Course of Murine Intestinal Eimeriosis

Saleh Al-Quraishy,<sup>1</sup> Mahmoud S. Metwaly,<sup>1</sup> Mohamed A. Dkhil,<sup>1,2,\*</sup> Mohamed M. Gewik,<sup>1</sup> Abdel-Moniem S. Hassan<sup>3</sup> and Rafat Zrieq<sup>4</sup>

<sup>1</sup>Department of Zoology, College of Science, King Saud University, Riyadh, Saudi Arabia

<sup>2</sup>Department of Zoology and Entomology, Faculty of Science, Helwan University, Cairo, Egypt

<sup>3</sup>Department of Biochemistry, Faculty of Agriculture, Fayoum University, Egypt

<sup>4</sup>Department of Biology, Faculty of Science for Girls at Alfaysalyah, King Abdulaziz University, Saudi Arabia

**Abstract.-** The current study was designed to evaluate the antagonistic effect of palm pollen extract (PPE) against *Eimeria papillata*-induced growth depression and metabolic disturbance in laboratory mice. Swiss albino mice were randomly divided into three groups. The first group represents control non-infected animals. Second and third groups were orally infected with  $1.5 \times 10^3$  sporulated *E. papillata* oocysts. The 3<sup>rd</sup> group was treated with a daily dose (150 mg/kg) of PPE for five successive days. All animals were sacrificed on day 5 *p.i.*, and samples were collected. Control non-infected mice had an average gain in their weights by about 18%, while infected mice lost their weights by about 7%. Upon treatment of infected mice with PPE, there was an average weight gain of about 5%. A state of disturbance in nutrient levels and systemic inflammatory response had been induced as a result of *E. papillata* infection. Blood glucose level and total proteins were elevated with concurrent decrease of carbohydrate and protein content in jejunum tissue. Also, infection caused hyperlipidemic status and disturbance in metal ion concentrations. Moreover, plasma enzymatic activities of lactate dehydrogenase, alanine transaminase and alkaline phosphatase were significantly elevated as a consequence of *E. papillata* infection. PPE could effectively restore carbohydrate, proteins, lipids and metal ions near to their normal values with diminishing the activity of the mentioned enzymatic biomarkers of inflammation. Finally, palm pollens can be used as an excellent food supplement to ameliorate the induced metabolic disturbance and growth depression associated with the intestinal coccidial infections.

**Key words:** Palm pollen, coccidiosis, growth and metabolic enhancer, *Eimeria papillata*, mice.

### INTRODUCTION

Coccidiosis is caused by multiple species of the protozoan parasite of the genus *Eimeria* (Apicomplexa : Eucoccidia : Eimeriidae). It can infect a wide variety of animals, including humans, birds and livestock (Pakandl, 2009). Coccidiosis has been controlled successfully for decades using mainly anticoccidial products. However, large-scale and long-term use of anticoccidial drugs had led to the worldwide development of resistance against all these drugs (Peek and Landman, 2011). So the necessity appears to use traditional medicines of natural plant origin to avoid problems with drug resistance and the adverse side effects of synthetic drug therapy (Lopez *et al.*, 2011; Dkhil *et al.*, 2013).

Pollen is a fine powder-like material produced by flowering plants which is considered to

be the male reproductive cells of flowering plants. Pollen and pollen products are important traditional herbal medicine widely used in the treatment of various diseases as it has many pharmacological functions as antimicrobial (Baltrusaityte *et al.*, 2007; Ozcan, 2004), antioxidative (Le Blanca *et al.*, 2009), anti-inflammatory (Choi, 2007), anti-toxicant (Eraslan *et al.*, 2008) and hepatoprotective (Uzbekova *et al.*, 2003) modulator. Up to date, palm pollen has not been examined for its activity against the induced metabolic disturbance and growth depression by the intestinal coccidial infection with *Eimeria* parasites. Such infections have a negative impact on animal growth and food utilization (Bhat *et al.*, 1996; Dkhil and Al-Quraishi, 2012) leading to

Abbreviations: ALP, alkaline phosphatase; ALT, alanine transaminase; CUV, crypt unit villi; HDLc, high density lipoprotein cholesterol; LDH, lactate dehydrogenase; LDLc, low density lipoprotein cholesterol; P.i., post infection; T, lipids; total lipids; T.C, total cholesterol; T, proteins; total proteins; PPE, palm pollen extract; T.Gs, triglycerides or triacylglycerols; VLDLc, very low density lipoprotein cholesterol.

\* Corresponding author: [mohameddkhil@yahoo.com](mailto:mohameddkhil@yahoo.com)

0030-9923/2014/0002-0423 \$ 8.00/0

Copyright 2014 Zoological Society of Pakistan

decreased weight, poor nutrition and low performance (Jithendran and Bhat, 1996) and finally huge economic losses (Bhat *et al.*, 1996). The current work aims to study if palm pollen extract could enhance growth and strengthen metabolism in mice infected with intestinal *E. papillata* infection.

## MATERIALS AND METHODS

### *Preparation of palm pollen suspension*

Palm pollen grains were kindly provided by the Department of Food and Nutrition Science, College of Food and Agricultural Science, King Saud University. The water suspension was prepared by mixing 0.5 g of palm pollen within 10 ml of sterile saline with vigorous shaking and vortexing. Then the solution was kept at water bath, 60°C for 90 min. This was followed by sonication within ultrasound probe (6 kHz) for 30 seconds. Samples were stored at 4°C overnight, followed by centrifugation at 300 g for 10 min. The clear supernatant was then separated into clear tubes and stored at 4°C until use (Metwaly *et al.*, 2014).

### *Preparation of E. papillata oocysts*

A self-healing strain of *E. papillata* was kindly provided by Prof. Mehlhorn of Heinrich Heine University, Duesseldorf, Germany. Several passage processes of *E. papillata* were performed in laboratory mice, followed by oocyst collection from faeces and sporulation process in potassium dichromate solution (2.5%). After that, the sporulated oocysts were washed several times with sterile saline and then surface-sterilized with sodium hypochlorite, and washed at least four times with sterile saline before oral inoculation as described by Schito *et al.* (1996). These oocysts were used to inoculate mice by oral gavaging of each mouse with  $1.5 \times 10^3$  sporulated oocysts of *E. papillata* suspended in 100 µl sterile saline.

### *Animals and experimental design*

Eighteen male Swiss albino mice (9-11 weeks) randomly divided into three groups, six mice per each group. The first group received saline and served as control. Second and third groups were orally infected with  $1.5 \times 10^3$  sporulated *E. papillata* oocysts. The third group was treated with a daily

dose (150 mg/kg) of PPE for five successive days. The dose and the route of injection were selected on the basis of the previous studies (Elberry *et al.*, 2011; Metwaly *et al.*, 2014). The experiments were approved by state authorities and followed Saudi Arabian rules for animal protection. Weight of mice was recorded at the beginning and the end of the experiment.

### *Biochemical analysis*

On day 5 *p.i.* of mice with *E. papillata*, the blood was collected from heart into heparinized tubes. Plasma was separated and kept at -20°C until use. Parts of jejunum were weighed and homogenized immediately in ice-cold phosphate buffered saline then centrifuged at 2000 g.×15 min at 4° C to give a final yield of (10% w/v) jejunal homogenate that were kept at -20° C until use. Blood plasma was analyzed using commercial kits (Biomérieux, Marcy l'Etoile, France) for glucose and total proteins, while, jejunum homogenate was used for the determination of total carbohydrate content using phenol-sulfuric acid method (Dubois *et al.*, 1979) and for measuring soluble protein content (Lowry *et al.*, 1951). In addition, plasma lipid fractions were assayed colorimetrically using commercially available kits (Biodiagnostic Company, Gizza, Egypt) for lipids, t. cholesterol, HDLc, phospholipids, and TGs. LDLc and VLDLc were calculated according to Van Horn *et al.* (1988). Moreover, enzymatic activities of ALT, ALP and LDH in blood were determined via kinetic ultraviolet method using available commercial kits (Biodiagnostic Company, Giza, Egypt) according to manual of manufacturer.

### *Histological examination and parasitic score*

Pieces of jejunum were freshly prepared, fixed in 10% neutral buffered formalin, and then embedded in paraffin. Sections were cut and stained with hematoxylin and eosin. According to Dommels *et al.* (2007) the total number of intracellular *Eimeria* stages was calculated within ten crypt unit villi (10 CUV).

### *Metal ion concentration*

Blood plasma samples from all groups were digested with concentrated nitric acid and hydrogen

peroxide as described by Bukhari *et al.* (2005). Levels of iron (Fe), potassium (K), magnesium (Mg), sodium (Na), and selenium (Se) were determined using the atomic emission spectrometer with inductivity coupled plasma iCAP-6500 Duo (Thermo scientific, United Kingdom).

### Statistical analysis

One-way ANOVA was carried out, and the statistical comparisons among the groups were performed with Duncan's test using a statistical package program (SPSS version 17.0). All *P* values are two-tailed and  $P < 0.05$  was considered as significant for all statistical analysis in this study.

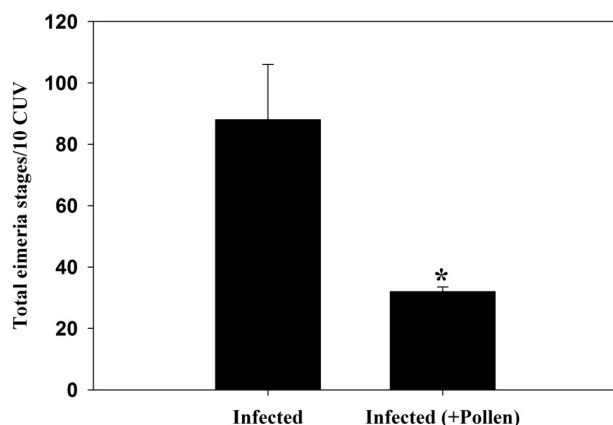


Fig. 1. Pollen induced alterations in the total number of developmental stages of *E. papillata* in jejunum tissue per ten CUV on day 5 *p.i.* All values are Means  $\pm$  SD. \* Significance change between infected treated and un-treated groups at  $P \leq 0.05$ .

## RESULTS

Oral infection of mice with sporulated *E. papillata* oocysts led to the intracellular development of parasite within jejunum tissue. On day 5 *p.i.*, palm pollen extract was able to reduce the number of intracellular *Eimeria* stages significantly ( $p \leq 0.05$ ) from 88 to 32 stages /10 CUV (Fig. 1). The infection was associated with some external pathological changes as general weakness, loss of appetite and diarrhoea. Treated mice with PPE were active, energetic, with increased appetite and their stool were not diarrhetic. Weight monitoring of study

animals showed that control uninfected mice had an average gain in weight by about 18%, while *E. papillata* infected mice had lost their weights by about 7% on day 5 *p.i.* (Fig. 2). Upon treatment of infected mice with PPE, they showed an increase in their weights by about 5% (Fig. 2).

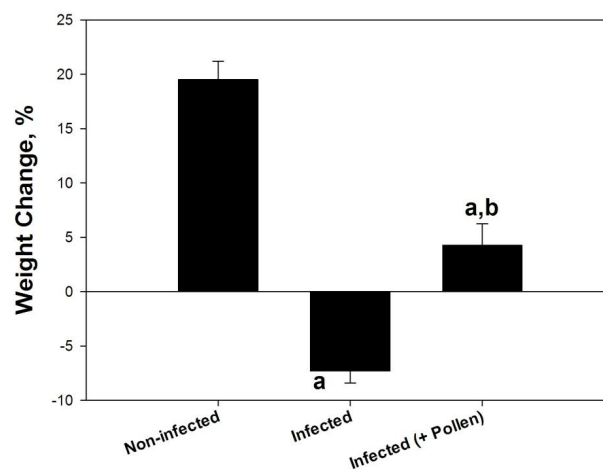


Fig. 2. Palm pollen improved weight loss due to infection with *E. papillata*. All values are Means  $\pm$  SD. a, Significant against non-infected control group at  $P \leq 0.05$ ; b, Significant against infected (- pollen) group at  $P \leq 0.05$ .

Intestinal infection with *E. papillata* was associated with a marked disturbance in the nutrient levels within blood and jejunum tissue. Total carbohydrate and soluble protein contents within jejunum tissue were diminished from 76.9 and 152.5 mg/g to 68.3 and 105.4 mg/g, respectively (Table I). This decrease was mutual to an increase in both plasma glucose and total proteins by about 7% and 11.4%, respectively. Treatment with palm pollen extract significantly ( $P \leq 0.05$ ) improved this nutrient levels in both blood and jejunal tissue (Table I). On day 5 *p.i.*, lipid fractions in blood of mice infected with *E. papillata* were significantly changed. There was a significant ( $P \leq 0.05$ ) elevation in the level of total lipids, total cholesterol and triglycerides to about 77.5%, 75% and 82%, respectively (Table II). Also, infection induced a marked decrease in HDLc from  $82.9 \pm 6.2$  mg/dl to  $75 \pm 4.7$  and that of phospholipids from  $7.2 \pm 0.3$  to  $4.7 \pm 0.23$  mg/dl ( $P \leq 0.05$ ) (Table II). In addition, both harmful fractions LDLc and VLDLc were significantly increased ( $P \leq 0.05$ ) from 10.2 mg/dl and 12.8 mg/dl

**Table I.- Palm pollen induced changes in glucose, jejunal carbohydrates, plasma proteins, and jejunal soluble proteins of mice infected with *E. papillata*.**

Group	Plasma glucose (mg/dl)	Jejunal carbohydrates (mg/g)	Plasma total proteins (g/dl)	Jejunal soluble proteins (mg/g)
Non-Infected	58.1±1.8	76.9±10.3	7.8±0.42	152.5±18.3
Infected (-Pollen)	62.3±2 <sup>a</sup>	68.3±6	8.8±0.33 <sup>a</sup>	105.4±12.8 <sup>a</sup>
Infected (+Pollen)	46.3±1.6 <sup>a,b</sup>	113.2±8.7 <sup>a,b</sup>	9±0.5 <sup>a,b</sup>	165.7±15 <sup>a,b</sup>

Values are Means ± SD. a: Significant against non-infected control group at  $p \leq 0.05$ , b: Significant against infected (- Pollen) group at  $P \leq 0.05$ .

**Table II.- Palm pollen induced changes in plasma lipids of mice infected with *E. papillata*.**

Group	T. Lipids (mg/dl)	T.C (mg/dl)	T.Gs (mg/dl)	HDLc (mg/dl)	LDLc (mg/dl)	VLDLc (mg/dl)	Phospholipids (mg/dl)
Non-Infected	371.1±22	105.9±6.4	64±3.8	82.9±6.2	10.2±0.9	12.8±0.8	7.2±0.3
Infected (-Pollen)	479.1±36 <sup>a</sup>	141.2±8.7 <sup>a</sup>	78±6.5 <sup>a</sup>	75±4.7	50.6±4.2 <sup>a</sup>	15.6±1.2 <sup>a</sup>	4.7±0.23 <sup>a</sup>
Infected (+Pollen)	352.4±19.5 <sup>b</sup>	126.5±4.6 <sup>a,b</sup>	58±5.2 <sup>a,b</sup>	101±9.8 <sup>a,b</sup>	13.9±1.1 <sup>a,b</sup>	11.6±0.6 <sup>b</sup>	7.3±0.35 <sup>b</sup>

Values are Means ± SD. a: Significant against non-infected control group a:  $p \leq 0.05$ , b: Significant against infected (- Pollen) group at  $P \leq 0.05$ .

to 50.6 mg/dl and 15.6 mg/dl, respectively (Table II). PPE showed an obvious lipid lowering activity. This can be seen from the significant ( $P \leq 0.05$ ) diminish in the level of T. lipids, T. cholesterol, T.Gs, LDLc and VLDLc nearby the control value of non-infected animals. Also, HDLc and phospholipid levels were restored to their control values (Table II). Moreover, the infection caused a marked disturbance in the metal ion concentration within blood. Fe, Mg and Se levels were markedly decreased by 20.2%, 36% and 30%, respectively. In addition, both K and Na ion concentration was significantly ( $P \leq 0.05$ ) increased from 166.5 µg/ml and 975.3 µg/ml to 219.8 µg/ml and 1512.7 µg/ml, respectively. PPE could effectively restore the level of studied metal ions near the control values (Table III).

A systemic inflammatory response was initiated as a consequence of the *E. papillata* infection. This was evidenced by significant increase in the activities of LDH, ALT and ALP by about 20%, 41% and 18%, respectively (Fig. 3). Palm pollen could significantly ( $P \leq 0.05$ ) reduce the activities of LDH, ALT and ALP by about 14%, 35% and 46.3%, respectively (Fig. 3).

**Table III.- Palm pollen induced changes in plasma metal ion concentrations of mice infected with *E. papillata*.**

Parameter (µg/ml)	Non-Infected	Infected (-Pollen)	Infected (+Pollen)
Ferrous	50±3.6	39.9±2.8 <sup>a</sup>	46.2±3.4 <sup>b</sup>
Potassium	166.5±11.2	219.8±8.3 <sup>a</sup>	202.1±10.3 <sup>a,b</sup>
Magnesium	36.5±3.2	23.4±1.8 <sup>a</sup>	28.2±2.1 <sup>a,b</sup>
Sodium	975.3±88	1512.7±245 <sup>a</sup>	1281.3±123 <sup>a,b</sup>
Selenium	2.0±0.02	1.4±0.0023 <sup>a</sup>	1.8±0.01 <sup>b</sup>

Values are Means ± SD. a, significant against non-infected control group at  $p \leq 0.05$ ; b, significant against infected (- Pollen) group at  $P \leq 0.05$ .

## DISCUSSION

Our results showed that palm pollen extract induced impairment in the endogenous development of *E. papillata* within jejunum tissue via reduction of the total number of *Eimeria* stages from 88 to 33 stages /10 CUV (Fig. 1). The high polyphenolic content in pollen extract (El-Berry *et al.*, 2011) exerts antimicrobial activities via disrupting cell walls and cell membranes and hence impaired permeability and finally microbial death (Graikou *et al.*, 2011; Carpes *et al.*, 2007).

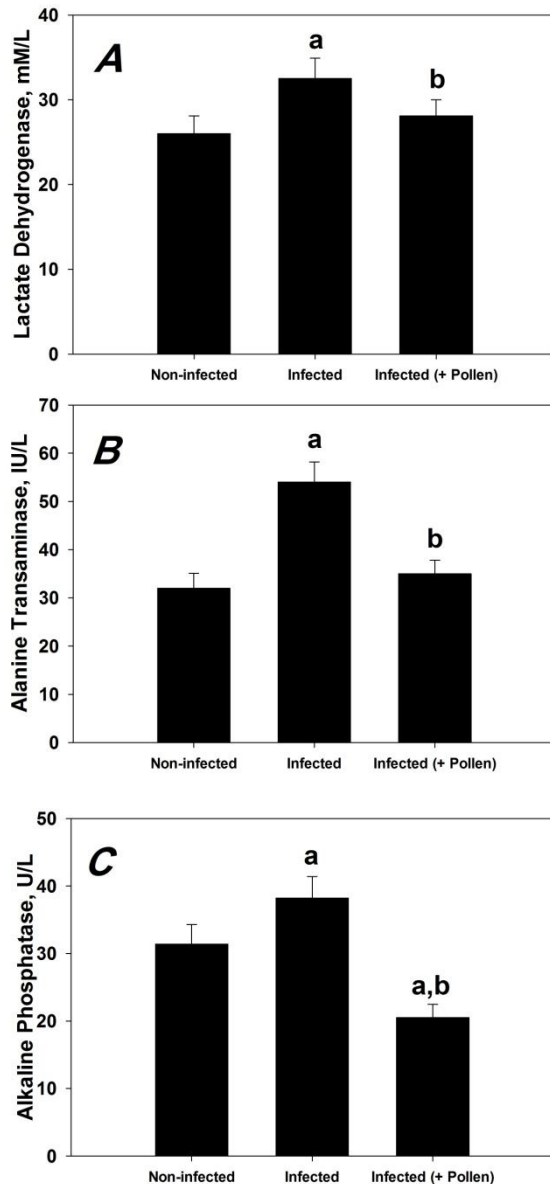


Fig. 3. Effect of palm pollen on the level of plasma LDH, ALP and ALT of mice infected with *E. papillata*. All values are Means  $\pm$  SD. A, Significant against non-infected control group at  $P \leq 0.05$ ; b, Significant against infected (- Pollen) group at  $P \leq 0.05$ . A, The activity of LDH, B, The activity of ALT and C, The activity of ALP.

Control uninfected mice grew normally and gain weight as a normal consequence of nutrition and food utilization resulting in an average weight gain of about 18 % (Fig 2). Intestinal *E. papillata*

infection had negative impact upon mice growth as revealed by the severe weigh loss of about 7% (Fig.2). PPE significantly inhibited the induced weight loss and mice gain an average weight of about 5% when compared to infected animals. The induced loss in body weight associated with intestinal coccidial infection may be due to poor nutrient intake, mal-absorption, mal-digestion and disrupted metabolic status (Ruff and Fuller, 1975; Allen and Danforth, 1984). Palm pollen grains are considered to be an excellent food resource as it contains a wide range of biochemically and nutritionally important substances as: minerals, trace elements, wide range of carbohydrates, organic acids, lipids, sterols, nucleic acids, free amino acids, vitamins and over 100 kinds of enzymes and co-factors (Hassan, 2011). Previous studies showed the great capacity of pollen as growth enhancer. Rabbits fed with pollen showed an increased body weight, conception rate, milk yield and improved biochemical profile of blood (Attia *et al.*, 2011). Also, chicken fed on pollen leads to a better development of the small intestine from the duodenum, jejunum and ileum, and subsequently promotes their digestion and absorption functions, body growth, and development (Wang *et al.*, 2007). In addition, pollen supplementation has a positive impact on performance of horses by increasing feed intake and nutrient retention (Turner *et al.*, 2006).

It was found that host cell metabolism is the most affected processes during the intestinal Eimerian infections (Lutz *et al.*, 2011) and these parasites have a great capacity to manipulate host cells for their benefits via scavenging available nutrients and essential host cell molecules (Hermosilla *et al.*, 2012; Forst, 2006). In addition, *Eimeria* infection causes rupture of intestinal mucosal membranes and hence altered food digestion and absorbance (Dkhil and Al-Quraishi, 2012; Metwaly *et al.*, 2012). Our data revealed that *E. papillata* infected mice showed a profound disturbance in carbohydrate content represented as elevated blood glucose level with concurrent decrease in carbohydrate content of jejunum tissue (Table I). In addition, the infection was associated with disrupted protein status as revealed by an increased protein in blood and reduced soluble protein content of infected jejunum tissue (Table I).

Intestinal coccidial infections have been classified as protein losing enteropathy (Kouwenhoven, 1971). Many studies proved that there's a decreased amount of total proteins in the infected tissues and increased rate of protein escape into the intestinal lumen via the ruptured intestinal wall associated with reduced absorption of amino acids and decreased digestibility of protein (Sharma and Fernando, 1973; Bangoura and Daugscies, 2007). The necessity to keep glucose energy source in its normal range in blood leads to stress-induced secretion of pancreatic glucagon and adrenal glucocorticoids that in turn activates both glycogenolysis and gluconeogenesis processes leading to breakdown of tissue carbohydrate store (Feritas *et al.*, 2008; Patra *et al.*, 2009; Mondal *et al.*, 2011) and hence increasing blood glucose level. Pollen is rich in protein, particularly free amino acids, and also abounds with carbohydrate, lipid, vitamins and minerals (Maruyama *et al.*, 2010). The increased lipid fractions in blood may be due to the disturbed energy homeostatic status by *Eimeria* infection which leads to stress-induced secretion of pancreatic glucagon and adrenal glucocorticoids that in turn activates both gluconeogenesis processes leading to breakdown of liver carbohydrate store (Feritas *et al.*, 2008; Patra *et al.*, 2009; Mondal *et al.*, 2011), followed by increased rate of fat mobilization and hydrolysis leading to increased level of plasma lipid fractions (Yvore and Minguy, 1972; Sharma and Fernando, 1973). Treated mice with PPE had much lower lipid fractions than untreated one with increased fractions of beneficial cholesterol (Table 2). The active constituents of pollens, especially poly-unsaturated fatty acids and sterols have hypolipidemic and hypocholesterolemic effects (Wojcicki *et al.*, 1987). They acts via stimulation of the microsomal 7  $\alpha$ -hydroxylation of cholesterol, an early step in the conversion of cholesterol to bile acids (Wojcicki *et al.*, 1986) and the lowering effect on the  $\beta$ -oxidation rate of fatty acids leading to decreased production of acetyl CoA, the precursor of cholesterol biosynthesis (Polanski *et al.*, 1996).

The main reason for the altered metal ion concentrations is the induced diarrheic status by the infection which leads to loss of water and electrolytes within faeces (Cirak *et al.*, 2004;

Bangoura and Daugscies, 2007). Palm pollen extract was previously proven to possess anti-diarrheal activities (Campos *et al.*, 2010) and hence protecting metal ion loss within feces. In addition, pollen is considered to be a perfect food of balanced nutritional values being a rich source of minerals including magnesium, calcium, copper, manganese, etc (Haro *et al.*, 2000) and hence can counteract the loss of mineral ions and reinstate metal ion homeostasis status. A state of systemic inflammatory response is associated with Eimerian infections (Al-Quraishy *et al.*, 2011; Dkhil and Al-Quraishi, 2012). This is obvious in our study as indicated by significant elevation in the activity of several enzymes as indicators of inflammation. Plasma activities of ALP, LDH and ALT were significantly increased as a consequence of *E. papillata* infection in mice (Fig. 3). PPE could effectively diminish that induced systemic inflammatory response via reducing levels of these inflammatory biomarkers and restoring their values near the control values of non-infected mice (Fig 3). Previous studies showed that pollen extract can reduce the activity of serum ALT and ALP and possesses hepatoprotective activities (Wojcicki *et al.*, 1985; Polanski *et al.*, 1996). This protective effect of pollen grains upon this systemic inflammatory response may be due to its contents of some flavonoids, such as quercetin and rutin, which exerts a strong activity against oxidative damage and inflammatory response (Campos *et al.*, 2003; Carpes *et al.*, 2007) and hence inhibiting *E. papillata* induced inflammatory changes within infected mice.

Collectively, our data indicates that treatment of infected mice with palm pollen extract could effectively inhibit the induced weight loss by *E. papillata* infection and significantly restored metabolic status of carbohydrates, proteins, lipids and metal ions to their normal levels.

## ACKNOWLEDGEMENTS

Authors extend their appreciations to the Deanship of Scientific Research at King Saud University for funding the work through the research group project no. RGP-VPP-002.

## REFERENCES

- ALLEN, P. C. AND DANFORTH, H. D., 1984. The effect of *Eimeria acervulina* infection on the metabolism of chick duodenal tissue. *Vet. Parasitol.*, **14**: 105-15.
- AL-QURAIISHY, S., METWALY, M.S., DKHIL, M.A., ABDEL-BAQI, A.S. AND WUNDERLICH, F., 2011. Liver response of rabbits to *Eimeria coecicola* infections. *Parasitol. Res.*, **110**: 901-911.
- ATTIA, Y. A., AL-HANOUN, A. AND BOVERA, F., 2011. Effect of different levels of bee pollen on performance and blood profile of New Zealand White bucks and growth performance of their offspring during summer and winter months. *J Anim. Physiol. Anim. Nutr.*, **95**: 17-26.
- BALTRUSAITYTE, V., VENSKUTONIS, P.R. AND CEKSTERYTE, V., 2007. Radical scavenging activity of different floral origin honey and beebread phenolic extracts. *Fd. Chem.*, **101**: 502-514.
- BANGOURA, B. AND DAUGSCIES, A., 2007. Influence of experimental *Eimeria zuernii* infection in calves on electrolyte concentrations, acid base balance and blood gases. *Parasitol. Res.*, **101**: 1637-1645.
- BHAT, T.K., JITHENDRAN, K. P. AND KURADE, N. P., 1996. Rabbit coccidiosis and its control. A review. *World Rabbit Sci.*, **4**: 37-41.
- BUKHARI, I.H., HASSAN, M. N., HALEEM, A. AND MAQBOOL, M. B., 2005. Role of metals (Cadmium and lead) in patients of hypertension and their relationship with ischemic heart disease. *Res. J. Agric. Biol. Sci.*, **1**: 190-194.
- CAMPOS, M.G., FRIGERIO, C., LOPES, J. AND BOGDANOV, S., 2010. What is the future of bee-pollen?. *Apiprod. Apimed. Sci.*, **2**: 131-144.
- CAMPOS, M.G., WEBBY, R. F., MARKHAM, K. R., MITCHELL, K. A. AND DA CUNHA, A. P., 2003. Aged induced diminution of free radicals scavenging capacity in bee-pollens and the contribution of constituent's flavonoids. *Fd. Chem.*, **5**: 742-745.
- CARPES, S. T., BEGNINI, R., DE ALENCAR, S. M. AND MASSON, M.L., 2007. Study of preparation of bee pollen extracts, antioxidant and antibacterial activity. *Ciênc agrotec Lavras*, **31**: 1818-1825.
- CHOI, E., 2007. Antinociceptive and antiinflammatory activities of pine (*Pinus densiflora*) pollen extract. *Phytother. Res.*, **21**: 471-475.
- CIRAK, V.Y., KOWALIK, S., BURGER, H., ZAHNER, H. AND CLAUSS, W., 2004. Effects of *Eimeria separata* infections on Na<sup>+</sup> and Cl<sup>-</sup> transport in the rat large intestine. *Parasitol. Res.*, **92**: 490-495.
- DKHIL, M.A. AND AL-QURAIISHI, S.A., 2012. Metabolic disturbance and hepatic tissue damage induced by *Eimeria papillata* infection. *Afr. Zool.*, **47**: 255-260.
- DKHIL, M.A., AL-QURAIISHY, S., ABDEL MONEIM A.E., 2013. Effect of pomegranate (*Punica granatum* L.) juice and methanolic peel extract on testis of male rats. *Pakistan J. Zool.*, **45**: 1343-1349.
- DOMMELS, Y.E., BUTTS, C.A., ZHU, S., DAVY, M., MARTELL, S., HEDDERLEY, D., BARNETT, M. P., MCNABB, W.C. AND ROY, N.C., 2007. Characterization of intestinal inflammation and identification of related gene expression changes in mdr1a<sup>(-/-)</sup> mice. *Genes Nutr.*, **2**: 209-223.
- DUBOIS, M., GILLES, K.A., HAMILTON, J.K., REBERS, P.A. AND SMITH, F., 1979. Colorimetric method for the determination of sugars and related substances. *Analyt. Chem.*, **28**: 350-356.
- ELBERRY, A., MUFTI, S.T., AL-MAGHRABI, J.A., ABDEL-SATTAR, E.A., ASHOUR, O.M., GHAREIB, S.A. AND MOSLI, H. A., 2011. Anti-inflammatory and antiproliferative activities of date palm pollen (*Phoenix dactylifera*) on experimentally-induced atypical prostatic hyperplasia in rats. *Inflammation*, **8**: 40-53.
- ERASLAN, G., KANBUR, M., SILICI, S., LIMAN, B., ALTINORDULU, S. AND KARABACAK, M., 2008. Evaluation of protective effect of bee pollen against propoxur toxicity in rat. *Ecotoxicol. Environ. Safety*, **72**: 931-937.
- FERITAS, F. L.C., ALMEIDA, K.S., MACHADO, R.Z. AND MACHADO, C.R., 2008. Lipid and glucose metabolism of broilers (*Gallus gallus domesticus*) experimentally infected with *Eimeria acervulina* Tyzzer, 1929 oocysts. *Brazilian Poult. Sci.*, **10**: 157-162.
- FORST, C.V., 2006. Host-pathogen systems biology. *Drug Discovery Today*, **11**: 220-227.
- GRAIKOU, K., KAPETA, S., ALIGIANNIS, N., SOTIROUDIS, G., CHONDROGIANNI, N., GONOS, E. AND CHINOI, I., 2011. Chemical analysis of Greek pollen - antioxidant, antimicrobial and proteasome activation properties. *Chem. Cent.*, **5**: 33-42.
- HARO, A., LÓPEZ-ALIAGA, I., LISBONA, F., BARRIONUEVO, M., ALFÉREZ, M.J. AND CAMPOS, M.S., 2000. Beneficial effect of pollen and/or propolis on the metabolism of iron, calcium, phosphorus, and magnesium in rats with nutritional ferropenic anemia. *Agric. Fd. Chem.*, **48**: 5715-5722.
- HASSAN, M.M.H., 2011. Chemical composition and nutritional value of palm pollen grains. *Global Biotechnol. Biochem.*, **6**: 01-07.
- HERMOSILLA, C., RUIZ, A. AND TAUBERT, A., 2012. *Eimeria bovis*: An update on parasite-host cell interactions. *Int. Med. Microbiol.*, **302**: 210-215.
- JITHENDRAN, K. P. AND BHAT, K. P., 1996. Subclinical coccidiosis in Angora rabbits—a field survey in Himachal Pradesh (India). *World Rabbit Sci.*, **4**: 29-32.
- KOUWENHOVEN, B., 1971. *Eimeria avervulina* infection in chickens: a parasitological and biochemical study (summary). *Netherland Vet. J.*, **4**: 112-114.
- LE-BLANCA, B. W., DAVIS, O. K., BOUE, S., DELUCCA,

- A. AND DEEBY, T., 2009. Antioxidant activity of Sonoran Desert bee pollen. *Fd. Chem.*, **115**: 1299-1305.
- LOPES, J., STANCIU, O. G., CAMPOS, M. G., ALMARAZ-ABARCA, N., MURADIAN, L. B. AND MARGHITAS, L. A., 2011. Bee pollen antioxidant activity - a review: achievements and further challenges. *Pharmacognosy*, **2**: 25-38.
- LOWERY, O. H., ROSENBROUGH, N. J., FARR, A. L. AND RANDALL, R. J., 1951. Protein measurement with the Folin Phenol reagent. *Biol. Chem.*, **193**: 265-275.
- LUTZ, K., SCHMITT, S., LINDER, M., HERMOSILLA, C., ZAHNER, H. AND TAUBERT, A., 2011. *Eimeria bovis*-induced modulation of the host cell proteome at the meront I stage. *Mol. Biochem. Parasitol.*, **175**: 1-9.
- MARUYAMA, H., SAKAMOTO, T., ARAKI, Y. AND HARA, H., 2010. Anti-inflammatory effect of bee pollen ethanol extract from *Cistus* sp. of Spanish on carrageenan-induced rat hind paw edema. *BMC Comp. Altern. Med.*, **10**: 30-40.
- METWALY, M. S., DKHIL, M. A. AND AL-QURAI SHY, S., 2012. The potential role of *Phoenix dactylifera* on *Eimeria papillata*-induced infection in mice. *Parasitol. Res.*, **111**: 681-687.
- METWALY, M. S., DKHIL, M. A. AND AL-QURAI SHY, S., 2014. Anti-coccidial and anti-apoptotic activities of palm pollen grains on *Eimeria papillata* induced infection in mice. *Biologia*, **69**: 254-254.
- MONDAL, D.K., CHATTOPADHYAY, S., BATABYAL, S., BERA, A.K. AND BHATTACHARYA, D., 2011. Plasma biochemical indices at various stages of infection with a field isolate of *Eimeria tenella* in broiler chicken. *Vet. World*, **4**: 404-409.
- OZCAN, M., 2004. Inhibition of *Aspergillus parasiticus* NRRL 2999 by pollen and propolis extracts. *Med. Food*, **7**: 114-116.
- PAKANDL, M., 2009. Coccidia of rabbit: a review. *Folia Parasitol.*, **56**:153-166.
- PATRA, G., RAJKHOWA, T. K., ALI, M.A., TIWARY, J.G. AND SAILO, L., 2009. Studies on clinical, gross, histopathological and biochemical parameters in broiler birds suffered from *Eimeria necatrix* Infection in Aizawl District of Mizoram. *Indian Int. Poult. Sci.*, **8**: 1104-1106.
- PEEK, H. W. AND LANDMAN, W. J., 2011. Coccidiosis in poultry: anticoccidial products, vaccines and other prevention strategies. *Vet. Quart.*, **31**: 143-161.
- POLANSKI, M., CZARNECKI, R. AND WORON, J., 1996. The hepatoprotective and hypolipidemic effect of flower pollen lipid extract in androgenized rats. *Folia Med. Craco.*, **37**: 89-95.
- RUFF, M. D. AND FULLER, H. L., 1975. Some mechanisms of reduction of carotenoid levels in chickens infected with *Eimeria acervulina* or *E. tenella*. *Nutrition*, **105**: 1447-1456.
- SCHITO, M. L., BARTA, J. R. AND CHOBOTAR, B., 1996. Comparison of four murine *Eimeria* species in immunocompetent and immunodeficient mice. *Parasitology*, **82**: 255-262.
- SHARMA, V. D. AND FERNANDO, M. A., 1973. Effect of *Eimeria acervulina* infection on nutrient retention with special reference to fat malabsorption in chickens. *Canadian J. Comp. Med.*, **39**: 146-154.
- TURNER, K. K., NIELSEN, B.D., O'CONNOR, C.I. AND BURTON, J.L., 2006. Bee pollen product supplementation to horses in training seems to improve feed intake: a pilot study. *Anim. Physiol. Anim. Nutr.*, **90**: 414-420.
- UZBEKOVA, D.G., MAKAROVA, V., KHVOYNITSKAYA, L.G. AND SLEPNEV, A.A., 2003. Evaluation of bee-collected pollen influence on lipid peroxidation, antioxidant system and liver function in old animals. *Hepatology*, **38**: 203-208.
- VAN HORN, L., ANNEMIDY, L., LIU, K., LIAO, Y., BALLEW, C., KIN, J. AND STAMLER, J., 1988. Serum lipid response to a fat modified, oat meal-enhanced diet. *Prevent. Med.*, **17**: 377-386.
- WANG, J., LI, S., WANG, Q., XIN, B. AND WANG, H., 2007. Trophic effect of bee pollen on small intestine in broiler chickens. *Med. Food*, **10**: 276-280.
- WOJCICKI, J., HINEK, A. AND SAMOCHOWIEC, L., 1985. The protective effect of pollen extracts against allyl alcohol damage of the liver. *Arch. Immunol. Therap. Exp.*, **33**: 418-419.
- WOJCICKI, J., SAMOCHOWIEC, L., BARTLOMOWICZ, B., HINEK, A., JAWORSKA, M. AND GAWRONSKA, S., 1986. Effect of pollen extract on the development of experimental atherosclerosis in rabbits. *Atherosclerosis*, **62**: 39-45.
- WOJCICKI, J., SAMOCHOWIEC, L., KADLUBOWSKA, O. AND KOWNACKA, A., 1987. Study on the antioxidant properties of pollen extracts. *Arch. Immunol. Therap. Exp.*, **35**: 725-729.
- YVORE, P. AND MAINGUY, P., 1972. Influence de la coccidiose duodénale sur la teneur en caroténoïdes du sérum chez le poulet. *Ann. Vet. Res.*, **3**: 381-387.

(Received 16 January 2014, revised 23 February 2014)